

# ***Crenosoma vulpis* (Dujardin 1844) (Nematoda, Crenosomatidae) in foxes in Vojvodina Province, Serbia**

Verica Simin<sup>1\*</sup>, Vesna Lalošević<sup>2</sup>, Annamaria Galfi<sup>2</sup>, Milovan Božić<sup>1</sup>,  
Nemanja Obradović<sup>1</sup> and Dušan Lalošević<sup>1,3</sup>

<sup>1</sup> Pasteur Institute of Novi Sad, Hajduk Veljkova 1, 21000 Novi Sad, Serbia

<sup>2</sup> Department of Veterinary Medicine, Faculty of Agriculture, University of Novi Sad, Trg Dositeja Obradovića 8, 21000 Novi Sad, Serbia

<sup>3</sup> Faculty of Medicine, University of Novi Sad, Hajduk Veljkova 3, 21000 Novi Sad, Serbia

Received for Review: 25. 01. 2012. / Accepted: 13. 03. 2012.

**Summary.** *Crenosoma vulpis* is a lung worm which affects carnivorous mammals. Data on the presence of *C. vulpis* in foxes in Serbia is lacking. In the present study, *C. vulpis* was found in the fox population of Vojvodina Province, Serbia, during the course of examinations for *Eucoleus aerophilus*. Foxes were collected throughout Vojvodina Province: most of the foxes had either been previously suspected of rabies or regularly shot in 2011. Carcasses were opened and tracheas were taken from larynx to bifurcation, and preserved in 30% ethanol for later examination. For the purpose of examination, the tracheas were opened on the anterior side using scissors. Parasites were collected under a stereomicroscope by scraping of mucosa and wet-mounted in glycerin-ethanol or lactophenol. *Crenosoma vulpis* was found in 5 out of 38 foxes, for a prevalence rate of 13.15%. A total of 8 male, 15 female and 45 larvae was found. Cohabitation of foxes with stray dogs and cats may be a potential source of parasite transmission in urban environments.

**Keywords:** *Crenosoma vulpis*, foxes, prevalence, Serbia, Vojvodina

## **Introduction**

*Eucoleus aerophilus* syn. *Capillaria aerophila* (Creplin, 1839) and *Crenosoma vulpis* (Dujardin, 1844) are respiratory parasites of wild and domestic canidae and various carnivores around the world, including foxes. *Eucoleus aerophilus* adult worms live embedded in the epithelium of bronchi and trachea of the definitive host (Traversa et al. 2009, 2011), and, rarely, in the bronchiolar epithelium (Nevárez et al. 2005). *Eucoleus aerophilus* has a direct life cycle, which may include paratenic hosts such as various types of earthworms. Infestation of animals is typically a result of ingestion of embryonated eggs from the ground or larvae from paratenic hosts. After ingestion of embryonated eggs, freed larvae penetrate the intestinal wall, gaining access to the circulatory system, and are distributed to the lungs, where they become reproductively mature: reaching full maturity

within two to six weeks of infection (Anderson 2000). *Eucoleus aerophilus* infections in red foxes are considered to be an enzootic disease.

*Crenosoma vulpis* is endemic in the red fox population in Europe, Canada and North America. Adult lungworms infect bronchioles, bronchi and trachea of wild and domestic canids (Bihr and Conboy 1999). Both *C. vulpis* and *E. aerophilus* parasites cause parenchymal damage in the hosts' lung and chronic bronchitis, followed by sneezing, difficult breathing and either a chronic dry or wet/productive cough. Infection by large numbers of parasites may result in death, as a consequence of bronchopneumonia and severe respiratory insufficiency (Holmes and Kelly 1973; Bowman et al. 2002; Taylor et al. 2007). In addition to the aforementioned symptoms, *Eucoleus aerophilus* infections also manifest as bad fur quality and poor growth in the case of animals with

compromised immune system (Nevárez 2005).

A recent report of the first human case of pulmonary capillariasis significantly roused interest in these parasitic diseases in Serbia. An elderly female patient presented with respiratory tract symptoms, such as persistent cough with purulent expectoration, high temperature, increased number of leukocytes and blood eosinophilia up to 21%, with symptoms lasting for approximately two months. The clinical symptoms of pulmonary capillariasis resemble the clinical symptoms of bronchial carcinoma, the patient's initial diagnosis (Lalošević et al. 2008). According to Traversa et al. (2009), Capillaridae are a widely distributed group of nematodes. However, *E. aerophilus* infections in animals tend to be underestimated and neglected, mostly because the majority of cases show no symptoms and are often not diagnosed at all. In addition, Lalošević et al. (2009) emphasized that successful diagnostics of pulmonary capillariasis is usually achieved by the use of a pathological section method.

In the course of examination of capillariasis in the fox population in Vojvodina Province, Serbia, *C. vulpis*, another nematode parasite of the respiratory tract, was found. Because of the lack of data on this parasitic disease in Serbia in the literature, the present study was undertaken to examine the prevalence of *C. vulpis* in foxes in Vojvodina Province, Serbia.

## Materials and methods

The research sample for the present study included 38 foxes collected from various sites throughout Vojvodina, Serbia. Samples were collected in 2011 and sent to the Pasteur Institute of Novi Sad as a part of regulatory procedure related to rabies diagnostics.

Using the pathological section method, trachea samples were extracted from the fox carcasses. After test samples had been prepared, each trachea was opened to bifurcation and then preserved in 30% ethanol for at least 72 hours for the purpose of fixation. Next, fixed tracheas were carefully examined under a dissecting microscope to look for the presence of adult nematodes and larvae. Adult parasites found in the epithelium of trachea were extracted with a needle and wet-mounted in 50% glycerin-ethanol.

For the purpose of collecting *C. vulpis* adults and larvae, the epithelium of each trachea was carefully

examined and mucosa scrapings were wet-mounted in glycerin-ethanol and examined under an Olympus Vanox optical microscope at low magnifications of 10x and 40x. Parasitic species were determined according to morphological features described by Georgi and Georgi (1991) and Anderson (2000).

The number of positive samples versus the total number of samples, sex structure of the parasites, and the number of larvae in a positive sample are given in Table 1.

## Results

Adult worms and larvae of *C. vulpis* were found in 5 out of 38 examined fox tracheas (13.15%). With respect to gender, female foxes appeared to have a higher incidence of infection: 15 females (65.22%) were infected versus 8 males (34.78%). *Crenosoma* larvae were found in the tracheas of 3 out of 5 foxes. Adult male and female worms and nematode larvae were found together in the trachea of 1 fox (Fig. 1 and Fig. 2). Two foxes had only *C. vulpis* larvae and 2 foxes had either male or female adult worms (Table 1, Fig. 1, Fig. 2).

## Discussion

The presence of *C. vulpis* has been confirmed in foxes in Vojvodina, Serbia, with prevalence rate of approximately 13%. The prevalence of *C. vulpis* in red foxes is 24% in Hungary (Sréter et al. 2003), 13-18% in Spain (Miquel et al. 1994), 4.5% in the Netherlands (Borgsteede 1984), 24.9% in Austria (Lassnig et al. 1998) and 28.2% in Great Britain (Willingham et al. 1996). Interestingly, it has recently been shown that this nematode is the leading cause of respiratory diseases in domestic dogs in Spain, Portugal, Switzerland and Germany (Unterer et al. 2002; Barutzki and Schaper 2009; Madeira de Carvalho et al. 2009).

*Crenosoma vulpis* infections in dogs and cats present serious problems for veterinary medicine, both because of possible clinical manifestations and the fact that these infections are difficult to recognize on the basis of only clinical signs of the disease. Specifically, *Aelurostrongylus abstrusus* and *E. aerophilus* parasite infestations have either the same or similar clinical signs as other infectious and non-


infectious inflammatory diseases.

*Crenosoma* infection in foxes are relatively rare, but transmission from dogs is possible and has been recently recorded in Europe, where various clinical manifestations were described (Unterer et al. 2002; Rinaldi et al. 2007).

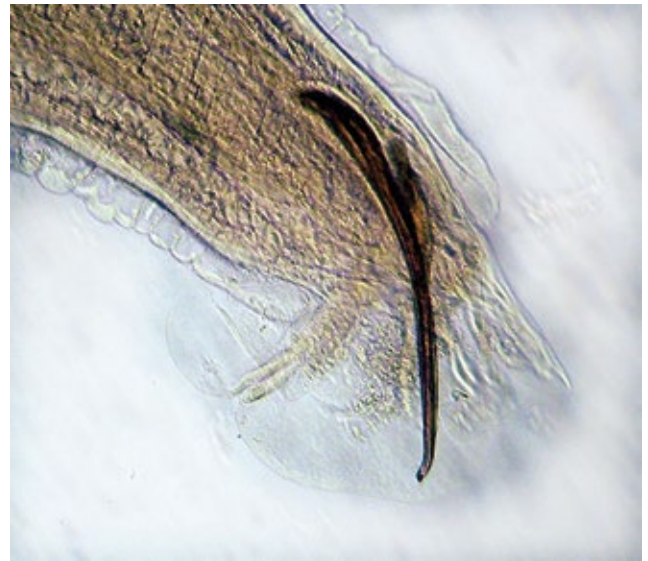
The gradual increase in the population of stray and abandoned dogs in urban and rural areas increases the danger of their close contacts with foxes, which might result in increased risk of zoonotic transmission of parasites.

**Table 1.** Number of adults and larvae of *Crenosoma vulpis* found in foxes in Vojvodina Province, Serbia.

Fox No.	Male	Female	Larvae
1	–	–	40
2	7	14	2
3	–	–	3
4		1	
5	1		
Total	8	15	45



**Figure 1.** Anterior end of female *Crenosoma vulpis* (x200).



**Figure 2.** Posterior end of male *Crenosoma vulpis* with spicules (x100).

## Acknowledgements

This study was supported by Ministry of Education and Science of Serbia, grant № TR 31084.

## References

- Anderson RC. 2000. Nematode Parasites of Vertebrates. Their Development and Transmission. 2nd ed. Guilford, UK: Cabi Publishing.
- Barutzki D, Schaper R. 2009. Natural infections of *Angiostongylus vasorum* and *Crenosoma vulpis* in dogs in Germany (2007–2009). Parasitology Research. 105:39–48.
- Bihr T, Conboy GA. 1999. Lungworm (*Crenosoma vulpis*) infection

- in dogs on Prince Edward Island. Canadian Veterinary Journal. 40:555–559.
- Borgsteede FHM. 1984. Helminth parasites of wild foxes (*Vulpes vulpes* L.) in The Netherlands. Zeitschrift fur Parasitenkunde. 70:281–285.
- Bowman DD, Hendrix CM, Lindsay DS, Barr SC. 2002. Feline Clinical Parasitology. Ames Iowa State University Press: Blackwell Science Company.
- Georgi JR, Georgi ME. 1991. Canine Clinical Parasitology. Philadelphia: Lea & Febinger.
- Holmes PR, Kelly JD. 1973. *Capillaria aerophila* in the domestic cat in Australia. Australian Veterinary Journal. 49:472–473.
- Lalošević D, Lalošević V, Klem I, Stanojev-Jovanović D, Pozio E. 2008. Pulmonary Capillariasis Mimicking Bronchial Carcinoma. The American Journal of Tropical Medicine and Hygiene. 78(1):14–16.
- Lalošević D, Lalošević V, Prašović S, Španović J, Nikolić N. 2009. Kapilarijaza respiratornog trakta kod lisica iz Vovodine [Capillariasis of the respiratory tract of foxes in Vojvodina]. Annals of scientific work at the Faculty of Agriculture in Novi Sad. 33(1):132–137. Serbian.
- Lassnig H, Prosl H, Hinterdorfer F. 1998. Zur Parasitenfauna des Rotfuchses (*Vulpes vulpes*) in der Steirermark. Wiener Tierärztlichen Monatsschrift. 85:116–122.
- Madeira de Carvalho LM, Pereira da Fonseca LM, Gomes L, Meireles JM. 2009. Lungworms in domestic and wild carnivores in Portugal rare parasites or rarely diagnosed? Proceedings of the Bayer Angiostrongylosis Forum, 19th Annual Congress of the European College of Veterinary Internal Medicine – Companion Animals: 9 September 2009; Porto, Portugal Bayer Animal Health GmbH, 28.
- Miquel J, Torres J, Casanova JC, Feliu C. 1994. Helminths paràsits de carnívors silvestres a Catalunya. Particularitats de les faunes del Montseny. Treballs del Museu de Granollers-Ciències Naturals, Granollers. 166 p.
- Nevárez A, Lopez A, Conboy G, Ireland W, Sims D. 2005. Distribution of *Crenosoma vulpis* and *Eucoleus aerophilus* in the lung of free-ranging red foxes (*Vulpes vulpes*). Journal of Veterinary Diagnostic Investigation. 17(5):486–489.
- Rinaldi L, Calabria G, Carbone S, Carrella A, Cringoli G. 2007. *Crenosoma vulpis* in dog: first case report in Italy and use of the FLOTAC technique for copromicroscopic diagnosis. Parasitology Research. 101(6):1681–1684.
- Sréter T, Széll Z, Marucci G, Pozio E, Varga I. 2003. Extraintestinal nematode infections of red foxes (*Vulpes vulpes*) in Hungary. Veterinary Parasitology. 115(4):329–334.
- Taylor MA, Coop RL, Wall RL. 2007. Veterinary Parasitology. Oxford, UK: Blackwell Publishing.
- Traversa D, Di Cesare A, Lia RP, Castagna G, Meloni S, Heine J, Strube K, Milillo P, Otranto D, Meckes O, et al. 2011. New Insights into Morphological and Biological Features of *Capillaria aerophila* (Trichocephalida, Trichuridae). Parasitology Research. 109:S97–S104.
- Traversa D, Di Cesare A, Milillo P, Iorio R, Otranto D. 2009. Infection by *Eucoleus aerophilus* in dogs and cats: Is another extra-intestinal parasitic nematode of pets emerging in Italy? Research in Veterinary Science. 87:270–272.
- Unterter S, Deplazes P, Arnold P, Flückiger M, Reusch CE, Glaes TM. 2002. Spontaneous *Crenosoma vulpis* infection in 10 dogs: laboratory, radiographic and endoscopic findings. Schweizer Archiv für Tierheilkunde. 144:174–179.
- Willingham AL, Ockens NW, Kapel CM, Monrad J. 1996. A helminthological survey of wild red foxes (*Vulpes vulpes*) from the metropolitan area of Copenhagen. Journal of Helminthology. 70(3):259–263.